

## A case of Polycythemia: diagnostic dilemma

Jadhav M.N.<sup>1</sup>, Patil P.<sup>2</sup>, Patil R.K.<sup>3</sup>, Kittur S.K.<sup>4</sup>, Kesarkhane M.M.<sup>5</sup>

<sup>1</sup>Dr. Meena N. Jadhav, Associate Professor, <sup>2</sup>Dr. Priya Patil, Assistant Professor, <sup>3</sup>Dr. Rashmi K. Patil, Associate Professor, <sup>4</sup>Dr. Shreekant K. Kittur, Professor & HOD; <sup>1,2,3,4</sup>authors are affiliated with Department of Pathology, Belagavi Institute of Medical Sciences, Belagavi, Karnataka, India, <sup>5</sup>Dr. Milind M. Kesarkhane, Pathology, Assistant Professor, Department of Immunohematology and Blood Transfusion, Government Medical College, Miraj, Maharashtra, India.

**Corresponding Author:** Dr. Priya Patil, Assistant Professor, Department of Pathology, Belagavi Institute of Medical Sciences, Belagavi, Karnataka, India. E-mail id: drpriyapatil03@gmail.com

### Abstract

Approach to a case of polycythemia is initially to distinguish relative from absolute polycythemia; then to distinguish Polycythemia Vera (PV) from secondary polycythemia. Finally, the etiology of secondary polycythemia has to be ascertained. A certain number of patients cannot be easily classified as having either PV or secondary polycythemia due to diagnostic difficulties.

We present a case of 52-year-old male, chronic smoker, hypertensive and an asthmatic for whom a complete work up was attempted to rule out PV. There was a diagnostic difficulty as to consider this patient a case of secondary polycythemia or Gaisbock's syndrome. We were unable to measure the red cell mass in this patient (which will be normal in Gaisbock's syndrome and increased in secondary polycythemia). Patient underwent phlebotomy and was asymptomatic at discharge.

**Keywords:** Gaisbock's syndrome, JAK2 mutation, Phlebotomy, Polycythemia

### Introduction

The term "Polycythemia ("many cells") describes an increase in the total quantity or volume (mass) of red blood cells in the body. An increase in the concentration of erythrocytes is designated as erythrocytosis, which is further classified into absolute when it is due to increase in the red cell volume or mass and spurious/relative when it is due to reduced plasma volume [1].

Absolute polycythemia is further classified into primary and secondary. A classic example of primary absolute polycythemia is PV.

The examples of secondary absolute polycythemia are hypoxia produced by chronic lung diseases, carboxy hemoglobinemia associated with smoking and renal cell carcinoma [2,3].

Gaisbock's syndrome was first described in 1905 and refers to a symptom complex associated with polycythemia. This syndrome is unattributed to a diagnosis of PV or to a secondary erythrocytosis.

The risk factors for development of Gaisbock's syndrome in order of decreasing importance are male sex, hypertension, smoking, diuretic therapy, obesity, and emotional or physical stress.

Polycythemia in Gaisbock's syndrome has been attributed to decrease in plasma volume. In these cases, there is association with increase in blood viscosity and peripheral vascular resistance with a propensity to develop arterial and/or venous thromboses [4].

Here, we present a case of polycythemia in whom PV was ruled out by applying the diagnostic criteria for the diagnosis of myeloid neoplasms (Table 1) [5], leaving possibilities of secondary polycythemia or Gaisbock's syndrome.

Manuscript received: 4<sup>th</sup> April 2019

Reviewed: 10<sup>th</sup> April 2019

Author Corrected: 16<sup>th</sup> April 2019

Accepted for Publication: 20<sup>th</sup> April 2019

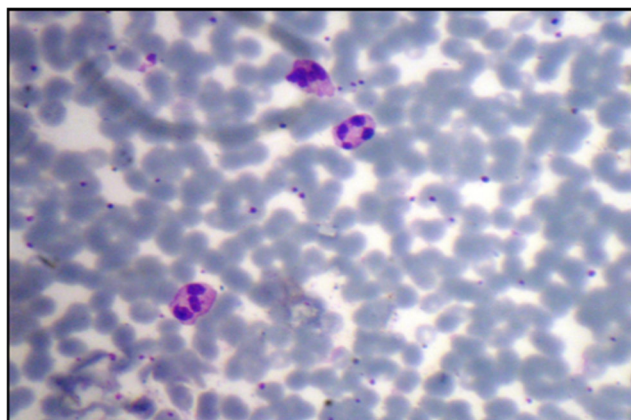
**Table 1: WHO 2016 criteria for Polycythemia Vera [5].**

<b>Major criteria</b>
1. Hemoglobin (Hb) >16.5 g/dL in men
Hemoglobin >16.0 g/dL in women
<b>OR</b>
Hematocrit (Hct) >49% in men
Hematocrit > 48% in women
<b>OR</b>
Increased red cell mass (RCM) >25% above mean normal predicted value
2. BM biopsy showing hypercellularity for age with trilineage growth (panmyelosis) including prominent erythroid, granulocytic, and megakaryocytic proliferation with pleomorphic, mature megakaryocytes (differences in size)
3. Presence of JAK2V617F or JAK2 exon 12 mutation
<b>Minor criteria</b>
Subnormal serum erythropoietin level
<b>Diagnosis of PV requires meeting either all 3 major criteria, or the first 2 major criteria and the minor criteria*</b>
*Criterion number 2 (BM biopsy) may not be required in cases with sustained absolute erythrocytosis: hemoglobin levels .18.5 g/dL in men (hematocrit, 55.5%) or .16.5 g/dL in women (hematocrit, 49.5%) if major criterion 3 and the minor criterion are present.

## Case Report

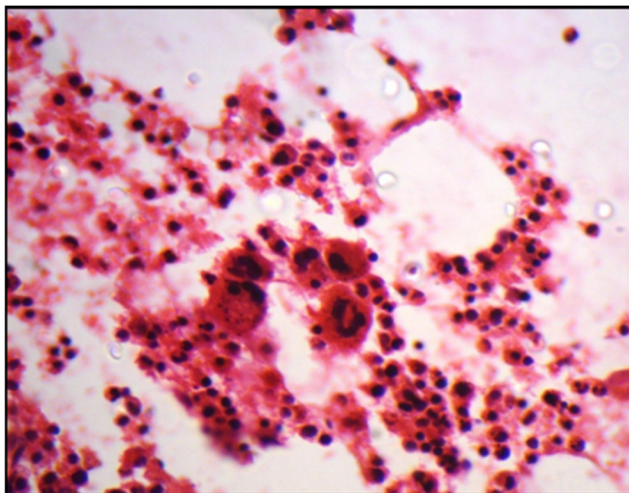
A 52-year male presented with headache for 20 days and breathlessness for 15 days. Previously he was admitted in another hospital for similar complaints 6 months back. He was a known case of bronchial asthma for 8 years and hypertension for 1 year for which he was on regular treatment. He was a chronic smoker for 20 years and a social drinker.

On examination, patient was obese with a body mass index (BMI) of 30. He had a ruddy complexion with congestion in the conjunctiva, tongue and oral cavity. The cardiovascular system and central nervous system were unremarkable. Blood pressure on several occasions was 160/100mmHg and respiratory rate 21/min. On auscultation, there were ronchi and on per abdominal examination there was mild hepatomegaly but no splenomegaly. Laboratory investigations revealed Hb of 19.8 gm%, hematocrit (Hct) 57%, red blood cell (RBC) count-6.3 million/cumm, total leucocyte count (TLC) 7,000cells/cumm, and a platelet count of 3.29 lakhs/cumm. Peripheral smear showed a normocytic normochromic blood picture with relative neutrophilia (Figure 1). Coagulation assays, serum electrolytes, random blood sugar, kidney and liver function tests were within normal range. Ultrasound examination of abdomen showed hepatomegaly. Rest of organs were unremarkable. 2D echo showed left ventricular hypertrophy with ejection fraction of 46%. Fundoscopic examination showed congestion of deep retinal vessels. The oxygen saturation levels (SpO<sub>2</sub>) on several occasions ranged from 91% to 92%.



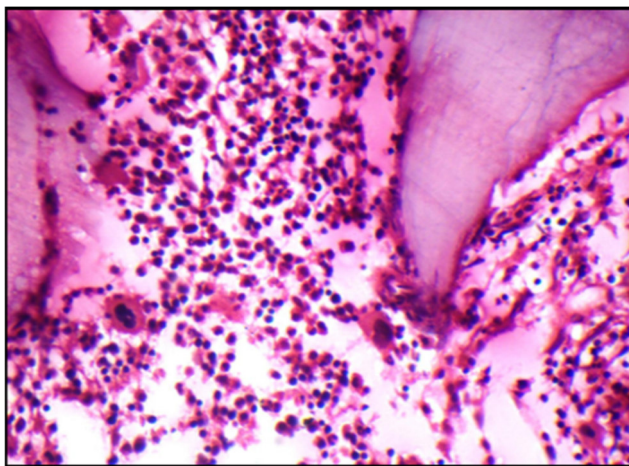
**Fig-1: Peripheral smear showing overcrowded RBC's with increased neutrophils (Leishman, x100).**

In view of high Hb and Hct, a possibility of PV was considered and further work up was done. Revised WHO 2016 criteria for diagnosis of myeloid neoplasms<sup>5</sup> was adopted to rule out the possibility of PV. Bone marrow aspiration was inadequate for opinion due to dilution by sinusoidal blood. It was submitted for cell block which showed clusters of megakaryocytes (Figure 2).



**Fig-2: Cell block of bone marrow aspiration showing clusters of megakaryocytes (H & E, x400).**

Bone marrow biopsy was done which showed erythroid and megakaryocytic hyperplasia with normal morphology of megakaryocytes (Figure 3).



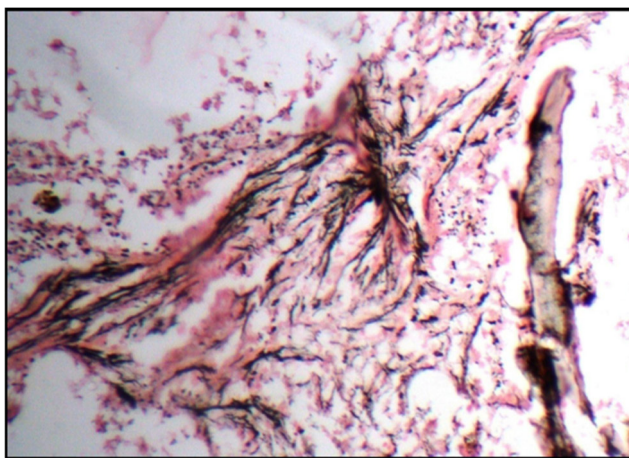
**Fig-3: Bone marrow biopsy showing increased erythroid precursors and megakaryocytes (H & E, x100).**

Reticulin stain showed increased fine reticulin fibers and in focal areas showed coarse reticulin fibers (grade 3 fibrosis-Figure 4).

Serum Erythropoietin (Epo) level was 11 IU/ ml (4 to 24 IU/ml). Cytogenetic analysis for *JAK2V617* mutation was negative. Thus, the possibility of PV was ruled out.

Differential diagnosis of secondary polycythemia and Gaisbock's syndrome were considered. We were unable to measure the red cell mass in this patient. Patient underwent phlebotomy and was asymptomatic for more than a year. Of late, he presented with symptoms of leg pain and breathlessness.

On admission, his laboratory investigations revealed hemoglobin of 14.5gm% and hematocrit-46%. Doppler could not be done to rule out deep vein thrombosis. He was managed symptomatically and discharged.



**Fig-4: Bone marrow biopsy showing increased coarse reticulin fibers (Reticulin, x100).**

## Discussion

Diagnosis of PV is currently according to the revised WHO 2016 criteria and is based on a composite assessment of clinical and laboratory features. Lowering of hemoglobin or hematocrit level in the revised WHO 2016 criteria simplifies the current first major diagnostic criterion for PV diagnosis and also carries therapeutic relevance because of the recent associations between increased thrombotic complications and borderline increased hematocrit (45% to 50%) in PV [5,6].

PV is more common above the age of 60 years [7,8]. In the current case, the patient is a 52-year male. The patient is obese, chronic smoker with an 8 year history of asthma (chronic lung disease) All these factors might have contributed to the development of secondary polycythemia. Palpable splenomegaly is included as one of the diagnostic criteria in the previous guidelines for diagnosis of polycythemia [2]. In the current case, there was no splenomegaly as confirmed on ultrasound scan.

Laboratory investigation revealed an increased hemoglobin level and hematocrit value thus fulfilling the first major criteria for PV [5]. Bone marrow showed erythroid and mild megakaryocytic hyperplasia with normal morphology of megakaryocytes in contrast to tri lineage hyperplasia and pleomorphic megakaryocytes seen in PV which is the second major criteria [5]. *JAK2V617* mutation was negative in the current case whereas, its presence is considered as third major criteria for diagnosis of PV [5].

Only 1 of the 3 major criteria were established in this case. The serum Epo level was normal so the minor criteria for diagnosis of PV was not met. Thus, the possibility of PV was ruled out leaving a diagnostic dilemma whether to consider it a case of secondary polycythemia or relative polycythemia. History of smoking and chronic lung disease favors secondary polycythemia. We were unable to

measure the blood carbon monoxide and carboxy haemoglobin levels which are increased in smokers [9]. Gaisbock's syndrome was thought of as the patient had four risk factors for Gaisbock's syndrome-male gender, hypertension, obesity and smoking. We were unable to measure the red cell mass in this patient which will be normal in Gaisbock's syndrome and increased in secondary polycythemia. The patient underwent phlebotomy and responded well.

Dayton and colleagues noted that in patients with severe chronic lung disease and secondary polycythemia, phlebotomy produced subjective benefit in the majority [10].

As patients with Gaisbock's syndrome are at increased risk of developing arterial and/or venous thromboses [4], bloodletting (phlebotomy) is being considered as an essential part of treatment for patients with Hct values greater than 54% [11].

Though a complete work up was attempted for this case, we faced the limitation of inability to measure red cell mass which would have aided in the accurate diagnosis of either secondary polycythemia or Gaisbock's syndrome.

## Conclusion

A detailed history, thorough physical examination and gamut of laboratory investigations are essential in differentiating primary and secondary polycythemias.

Phlebotomy in patients with secondary polycythemia and Gaisbock's syndrome brings an improvement in subjective wellbeing.

**Funding:** No funding sources

**Conflict of interest:** None declared

---

## References

1. Means TR. Erythrocytosis. In: Greer JP, Foerster J, Lukens JN, Rodgers GM, Paraskevas F, Glader B editors. *Wintrobe's Clinical Hematology Vol 1.11<sup>th</sup> edn.* Lippincott: Williams & Wilkins;2004 p.1225-1237.
2. McMullin MF. The classification and diagnosis of erythrocytosis. *Int J Lab Hematol.* 2008;30(6):447-459. doi: 10.1111/j.1751-553X.2008.01102.x. Epub 2008 Sep 23
3. McMullin MF, Bareford D, Campbell P, et al. Guidelines for the diagnosis, investigation and management of polycythaemia/erythrocytosis. *Br J Haematol.* 2005;130(2): 174-195.doi:https://doi.org/10.1111/j.1365-2141.2005.05535.x.
4. Stefanini M, Urbas JV, Urbas JE. Gaisböck's syndrome: its hematologic, biochemical and hormonal parameters. *Angiol.* 1978;29(7):520-533.doi:10.1177/000331977802900703.
5. Arber DA, Orazi A, Hasserjian R, Thiele J, Borowitz MJ, Le Beau MM et al. The 2016 revision to the World Health Organization classification of myeloid neoplasms and acute leukemia. *Blood.* 2016;127(20):2391-2405. doi: 10.1182/blood-2016-03-643544. Epub 2016 Apr 11.
6. Marchioli R, Finazzi G, Specchia G, Cacciola R, Cavazzina R, Cilloni D et al. Cardiovascular events and intensity of treatment in polycythemia vera. *N Engl J Med.* 2013;368(1):22-33. doi: 10.1056/NEJMoa1208500. Epub 2012 Dec 8.
7. Berlin NI. Diagnosis and classification of the polycythemia. *Semin Hematol.* 1975;12(4):339-351.
8. Tefferi A, Rumi E, Finazzi G, et al. Survival and prognosis among 1545 patients with contemporary polycythemia vera: an international study. *Leukemia.* 2013;27 (9): 1874-1881. doi: 10.1038/leu.2013. 163. Epub 2013 Jun 6.
9. Aitchison E, Russell N. Smoking: a major cause of polycythemia. *J R Soc Med* 1988;81(2): 89–91.
10. Dayton LM, McCullough RE, Scheinhorn DJ, Weil JV. Symptomatic and pulmonary response to acute phlebotomy in secondary polycythemia. *Chest* 1975;68:785-790. doi: https://doi.org/10.1378/chest.68.6.785.
11. Messinezy M, Pearson TC. Apparent polycythaemia: diagnosis, pathogenesis and management. *Eur J Haematol.*1993;51(3):125-131. doi:https://doi.org/10.1111/j.1600-0609.1993.tb00611.x.

---

### How to cite this article?

Jadhav M.N, Patil P, Patil R.K, Kittur S.K, Kesarkhane M.M. A case of Polycythemia: diagnostic dilemma. *Trop J Path Micro* 2019;5(11):954-958.doi:10.17511/jopm.2019.i11.19

---