

Maduramycosis in forearm -A case report

Jeyashambavi J.¹, B. Pushpa²

¹Dr. Jeya Shambavi. J. Assistant Professor, Department of Pathology, Aarupadai Veedu Medical College, Puducherry, India, ²Dr. B. Pushpa, Professor of Pathology, Department of Pathology, Kilpauk Medical College, Chennai, Tamilnadu, India.

Corresponding Author: Dr. Jeya Shambavi. J, Assistant Professor, Department of Pathology, Aarupadai Veedu Medical College, Puducherry, India, E-mail: jeenushambavi@gmail.com

Abstract

Mycetoma or Maduramycosis is a chronic granulomatous infection affecting skin and subcutaneous tissue and bone. Mycetoma is caused by Actinomycetes or by fungi such as Madurellamycetomi, Madurellagriesia etc. Eumycetoma is most commonly seen in males. The common site being foot and referred as Madura foot. The organisms present in soil are presumed to be inoculated directly after skin penetration with sharp objects like thorn and gain access to skin and subcutaneous tissue. Multiple nodules develop which suppurate and discharge grains through sinuses during active phase of the disease. We hereby report a case of Twenty year old female presented with painless swelling in right forearm which was clinically diagnosed as Lipoma and biopsy proved it to be Maduramycosis.

Key words: Maduramycosis, Mycetoma, Forearm

Introduction

Mycetoma is a chronic granulomatous infection involving skin, subcutaneous tissue and bone, caused by true fungi (eumycetoma) or filamentous bacteria (actinomycetoma) [1]. Mycetoma is predominantly a

disease of tropical region and was first reported in Madurai in India by Dr. John Gill in 1842 [2]. The most common site is Foot and hence the name 'Madura foot' [2].

Case Report

Twenty year old female presented to OPD department with complains of swelling in right forearm. The swelling was subcutaneous with smooth skin surface and was clinically diagnosed as Lipoma. FNAC was done which showed sheets of viable and degenerate polymorphs and histiocytes. Biopsy was done and the specimen was received. The specimen received measured 2.5x 1.5x1 cm. External surface of the specimen was grey white and cut surface was also greywhite with few blackish areas. Histopathological examination was done.H&E sections showed Club shaped structures surrounded by neutrophils, histiocytes, lymphocytes, plasma cells, eosinophils, and macrophages and multinucleate giant cells. A diagnosis of Madura mycosis was made.

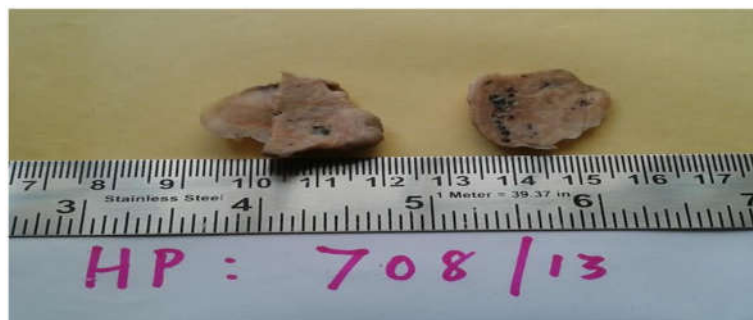

Fig: 1: Specimen received measured 3.5x3x2 cm with grey white cut surface showing few blackish areas.

Manuscript received: 10th August 2018

Reviewed: 20th August 2018

Author Corrected: 27th August 2018

Accepted for Publication: 30th August 2018

Case Report

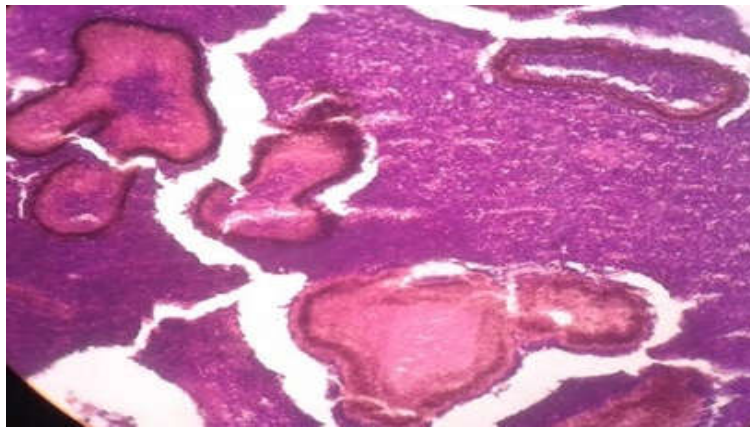


Fig 2:10x photomicrograph showing club shaped colonies

Discussion

Mycetoma or Madura mycosis is a common condition seen in Tropical and Sub tropical regions [2], affecting people of age 20 to 50 [3]. Males are five times more commonly affected [4,5]. Mycetoma can affect any part of the body. Most cases are usually seen in the feet (70%), followed by hands (12%), then legs and knee joints [4].

Mycetoma usually presents in individuals who walk barefoot in dry, dusty conditions. Minor trauma causes entry of pathogens into the skin from the soil [6]. The two main types of mycetoma are actinomycetic mycetoma and eumycetic mycetoma. Actinomycetoma is caused by a group of filamentous bacteria, of which *No cardiabrasiliensis* and *Streptomyces madurae* being most common. Eumycetoma is caused by a group of fungi with thick, septate hyphae, including *Allescheria boydii*, *Madurellagriesia* and *Madurellamycetomi* [7].

The incubation period ranges from several weeks to months [2]. Multiple discharging Sinuses develop and extension into the underlying fascia, muscle and bone is common. Rarely there is lymphatic dissemination to regional lymph nodes [8]. Actinomycetic mycetomas expand faster, are more invasive and have more sinuses than eumycotic variants.

Gram stain can be used in distinguishing Actinomycetoma and Eumycetoma. Grains of Actinomycetoma are Gram positive while grains of Eumycetoma are Gram negative [9,10]. The filaments and hyphae can be stained in biopsy samples with Gram stain (actinomycetoma) or Gomori methenamine silver or periodic acid-Schiff stains (eumycetoma). The granules of actinomycetoma consist of fine, branching filaments, only about 1 micron thick, whereas the granules of eumycetoma are composed of septate hyphae 4-5 microns thick [11]. The differentiation

between Eumycetoma and Actinomycetoma is important regarding treatment [13]. Radiological studies are useful in determining the Extent of lesions in bone and other tissues [14].

The differential diagnoses are chronic bacterial osteomyelitis, tuberculosis, Buruli ulcer, other deep fungal infections such as blastomycosis or coccidiomycosis [12].

Conclusion

Mycetoma is a chronic granulomatous lesion most commonly affecting males and most common site being feet and legs. Most cases present with draining sinuses.

This case is presented here because of the rare presentation of mycetoma in forearm in a female which presented without any discharging sinuses. Histopathological examination will be helping tool for a definitive diagnosis.

Funding: Nil, **Conflict of interest:** None initiated

Permission from IRB: Yes

References

1. Fahal AH. Mycetoma: a thorn in the flesh. *Trans R Soc Trop Med Hyg.* 2004 Jan;98(1):3-11.
2. Magana M. Mycetoma. *Int J Dermatol.* 1984 May; 23 (4): 221-36.
3. Lupi O, Tying SK, Mc Ginnis MR. et al. Tropical dermatology: fungal tropical diseases. *J Am Acad Dermatol.* 2005 Dec; 53 (6):931-51, quiz 952-4.
4. Mc Ginnis MR. Mycetoma. *Dermatol Clin.* 1996 Jan; 14 (1):97-104.

Case Report

5. Fahal AH, Suliman SH. Clinical presentation of mycetoma. Sudan Med. J 1994; 32: 46–66.
6. Lichon V, Khachemoune A. Mycetoma: a review. Am J Clin Dermatol. 2006;7(5): 315-21. doi:10. 2165/00128071-200607050-00005
7. Barnetson RS, Milne LJ. Mycetoma. Br J Dermatol. 1978 Aug;99(2):227-31.
8. Maiti PK, Ray A, Bandyopadhyay S. Epidemiological aspects of mycetoma from a retrospective study of 264 cases in West Bengal. Trop Med Int Health. 2002 Sep;7(9):788-92.
9. Zaias N, Taplin D, Rebell G. Mycetoma. Arch Dermatol. 1969 Feb; 99 (2):215-25.
10. Pilszczek FH, Augenbraun M. Mycetoma fungal infection: multiple organisms as colonizers or pathogens? Rev Soc Bras Med Trop. 2007 Jul-Aug; 40 (4) : 463-5.
11. Taralakshmi VV, Pankajalakshmi VV, Arumugam S, Subramanian S. Mycetoma caused by *Madurellamyces* in Madras. Australas J Dermatol. 1978 Dec; 19(3):125-9.
12. Kiran Alam, Veena Maheshwari, Shruti Bhargava. Histological Diagnosis of Madura Foot (Mycetoma): A Must for Definitive Treatment . J Glob Infect Dis. 2009 Jan-Jun; 1(1): 64–67. doi: 10. 4103/0974-777X.52985. PMID: PMC2840937.
13. Welsh O, Vera-Cabrera L, Salinas-Carmona MC. Mycetoma. Clin Dermatol. 2007 Mar-Apr; 25 (2): 195-202. DOI: 10. 1016/j. clindermatol. 2006. 05. 011.
14. Elmaataoui A, Elmoustachi A, Aoufi S, Lyagoubi M. Eumycetoma due to *Madurellamyces* from two cases of black grain mycetoma in Morocco. J. Mycol. Med., 2011;21(4):281-284.

How to cite this article?

Jeyashambavi J, B. Pushpa. Maduramycosis in forearm- A case report. Trop J Path Micro 2018; 4(6):431-433. doi:10.17511/jopm.2018.i06.02.
