

Histopathological study of skin tumours

Samanta M.¹, Mangal N.², Bhavani K.³, Koteeswaran G.⁴, Parmar P.C.⁵

¹Dr. Matariswa Samanta, Assistant Professor, Department of Pathology, ²Dr. Nitesh Mangal, Assistant Professor, Department of Community Medicine, ³Dr. K. Bhavani, Assistant Professor, ⁴Dr. G. Koteeswaran, Professor, ^{3,4}Authors are affiliated with Department of Pathology, Mahatma Gandhi Medical College & Research Institute, Puducherry, India, ⁵Dr. Piyushkumar C Parmar, Assistant Professor, Department of Community Medicine. ^{1,2,5}Authors are affiliated with Pacific Institute of Medical Science, Umarda, Udaipur, Rajasthan, India.

Corresponding Author: Dr. Nitesh Mangal, Assistant Professor, Department of Community Medicine, Pacific Institute of Medical Science, Umarda, Udaipur, Rajasthan, Email: niteshmangal20@hotmail.com

Abstract

Background: Skin tumour and their various histological types always creating a diagnostic difficulty. Histopathology is the gold standard for diagnosis in turn is used by clinicians to aid clinical outcome and also emphasizing certain key for valuable observation of certain tumours. **Objectives:** The study was conducted to find out the occurrence of different tumours of skin in MGMCRI and to classify skin tumours (WHO classification). **Methods:** The pathological features of 52 cases of Skin Tumours were analysed between May 2009 and May 2014. Section of skin tissue was studied by light microscopy after hematoxylin and eosin staining. **Results:** A total number of 52 cases of skin tumours were studied. Benign skin tumours constituted 44.23% while malignant skin tumours constituted 55.76% of all skin tumours. Intradermal nevus was the most common benign Skin tumours while Squamous Cell Carcinoma was the most common malignant tumours. **Conclusion:** Light Microscopic examination remains the standard technique for the diagnosis of the tumours. Although special stain and immunochemistry can be utilised in situation where the diagnosis cannot be confirmed on hematoxylin and eosin.

Key words: Skin Tumours, Squamous Cell Carcinoma, Light Microscopy

Introduction

Rudolph Virchow, the great pathologist more than a century ago considered skin to be a protective barrier for underlying viscera [1]. Considerable number of diseases can arise from the skin, as it is a complex organ [2]. Among all skin tumours, Keratinocytic tumours has significant impact on major health problem, although their mortality rate is comparatively low [3]. Malignant melanomas are important group of skin cancer, from a clinical point of view, although less common but more serious due to their high tendency to metastasis [4].

Cutaneous adnexal tumours describe as trouble some tumour by Cotton D [5]. Adnexal tumours are challenging to interpret because of its wide expanding list of entities, complicated nomenclature and the rarity of many of these tumours [6]. To give a meaningful clinical diagnosis, it is important to correlate the clinical differential diagnosis with the gross and microscopic

features [7]. However, immunohistochemical and electron microscopic studies are required to study the histogenesis and final typing of the skin tumours [8]. The study was conducted to find out the occurrence of different tumours of skin in MGMCRI and to classify skin tumours (WHO classification).

Materials and Methods

Place, type and duration of study: The present study was a descriptive study, conducted in Mahatma Gandhi Medical College and Research Institute, Pondicherry from May 2009 to May 2014.

Sampling methods and sample collection: The specimen was received in the Department of Pathology and gross finding like size, shape, colour and consistency were recorded. 52 cases of skin tumours were selected for the study. The Patient's clinical diagnosis and the histopathological features were noted. The material included punch biopsies and open excision specimens of various skin tumours. The specimens were

Manuscript received: 20th March 2018
Reviewed: 30th March 2018
Author Corrected: 6th April 2018
Accepted for Publication: 11th April 2018

Original Research Article

fixed in 10% formalin for 24 hrs and then four mm thick sections were cut from representative areas and submitted for routine processing. Section was studied by light microscopy after Haematoxylin and Eosin staining. The classification for the present study was based on the WHO classification of skin tumours (2005)[9].

Inclusion and exclusion criteria: Tumours and tumours like condition of epidermis along with melanocytic tumours and tumours of skin appendageal

Results

During the period of five years from May 2009 to 2014, there were 1256 cases of tumours were found. Out of which fifty-two cases were diagnosed as Skin Tumour which constitutes about 4.14% of all tumours. Out of fifty- two skin tumours, twenty–nine cases were malignant and twenty-three cases were benign.

Table-1: Distribution and Incidence of Benign and Malignant Tumour of Skin

	No. of Epidermal Tumours	No. of Adnexal Tumours	No. of Melanocytic Tumours
Benign	6 (11.54%)	8 (15.38%)	9 (17.31%)
Malignant	21(40.38%)	2 (3.85)	6 (11.54%)
Total no. of cases	27	10	15

Chi square value-12.0008, p value-0.002478 (p < 0.05)

Out of fifty-two cases, Malignant Epidermal Tumours were most common (40.38%) which followed by Benign Melanocytic Tumours (17.31%), Benign Tumours of Adnexal(15.38%), Benign Epidermal tumours (11.54%), Malignant Melanocytic Tumours (11.54%) and Malignant Adnexal Tumours (3.85%) [Table 1]. In the present study squamous cell carcinoma found to be as most common malignant epidermal tumours. [Figure:1]. Benign melanocytic tumours found to be most common benign tumours. Out of 9 cases of benign melanocytic tumours, 3 cases of intradermal nevus were most common followed by 2 cases of congenital nevi [Figure:2], 2 cases of compound naevus, one cases of junctional naevus and 1 case of melanocytic naevus.

Table-2: Incidence of Different Malignant Tumours of Skin.

Tumours	Number of Cases	Percentages (%)
Epidermal	21	72.41
Squamous Cell Carcinoma	14	48.27
Verrucous Squamous Cell Carcinoma	3	10.34
Basal Cell Carcinoma	7	24.13
Malignant melanoma	6	20.69
AcralLentiginous Melanoma	1	3.45
Superficial Melanoma	2	6.89
Nodular Melanoma	2	6.89
Ulcerated Melanoma	1	3.44
Adnexal	2	6.90
Proliferating Tricholemmoma	2	6.90
Total	29	100

In the study, epidermal tumour was commonest (72.41%) followed by Melanocytic (20.68%) and Adnexal (6.89%) [Table 2]. Two cases of malignant proliferating Tricholemmal tumour was found [Figure :3].

Table-3: Incidence of Skin Appendageal Tumours

Skin Appendageal Tumour	No of Benign Tumour	No. of Malignant Tumour	Total no. of Tumour
Tumour with Eccrine and Apocrine differentiation	7	-	7
Tumour with Hair follicle Differentiation	1	2	3
Total	8	2	10

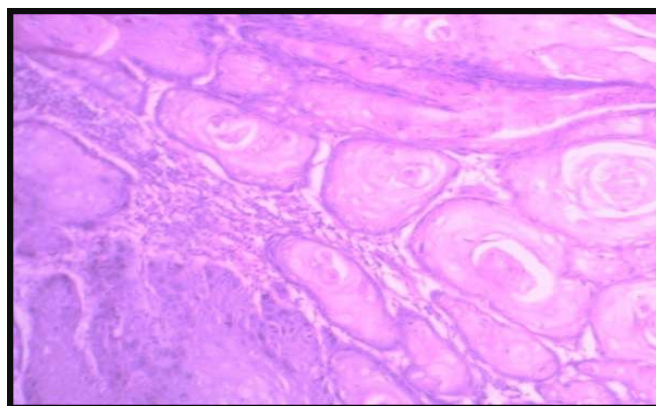


Figure-1: Microphotograph of Squamous cell carcinoma showing downward proliferation of island of squamous cell having nuclear pleomorphism, intracellular bridges with individual cell dyskeratosis, acanthosis [H&E x 40].

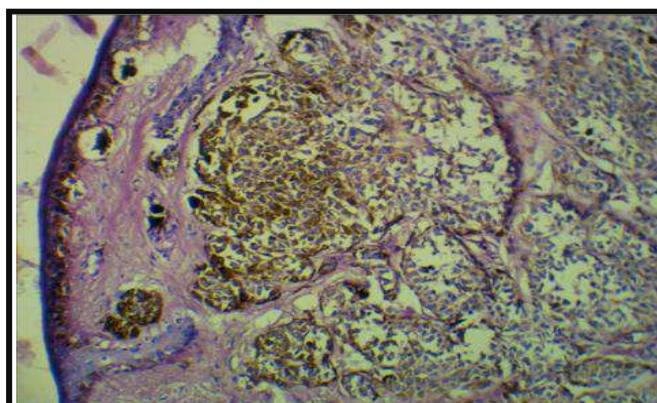


Figure-2: Microphotograph of congenital neuronevus showing proliferation of round naevus cell within and around upper dermal vessel wall nerve and sebaceous gland. (H & E x 40x)

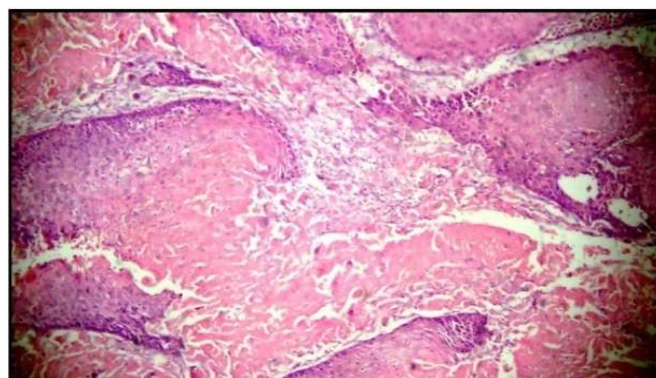


Figure-3: Micro Photograph of proliferating trichilemmal tumours showing Islands of basaloid cells having palisading arrangement and large keratinocytes with eosinophilic cytoplasm along with copious keratinization (H & E x 100) In the present study Benign Adnexal tumours forms the majority. Among the benign tumours the occurrence of tumour with Eccrine and Apocrine differentiation was highest (70%) followed by Hair Follicle Differentiation (10%) [Table 3].

Discussion

Although in India the skin malignancies are rare compared to western countries. In India skin malignancies constitute about 1 to 2% of all cancers. The percentage of malignant tumours was relatively higher in study done by Sonam SK et al (2011) (65.29%) compared to present study (55.76%) which may be due to increase number of referral received in higher centre [10].

Table-4: Comparative incidence of different malignant skin tumours in India.

Type of tumour	Deo SV et al (2005)[12]	Sonam SK et al (2011)[10]	Present study
Squamous cellCarcinoma	55.8%	64%	48.27%
Basal cellCarcinoma	18.1%	22.5%	24.14%
Malignant melanoma	26.1%	6.7%	20.69%
AdnexalCarcinoma	-	6.8%	6.90%

Numerous studies from India demonstrate that Squamous Cell Carcinoma is the most dominant skin cancer [11]. In the present study Squamous Cell Carcinoma was the most common malignant skin tumours among all skin cancers (48.27%) which is similar to the observation found by Deo SV et al study and Sonam SK et al [10,12]. Squamous Cell Carcinoma is more prevalent than basal cell carcinoma in our study and similar observation were found by Sonam SK et al (2011)[10], whereas Alakloby OM, et al (1983) [13] found basal cell carcinoma (62.2%) more prevalent than squamous cell carcinoma (37.8%). Seventeen cases of Squamous Cell Carcinoma in this study revealed Sheets and island of atypical dyskeratotic squamous cells proliferations in dermis and at many places forming keratin pearls.

Six cases of Seborrheic keratosis was found in this study, out of which two are showing Pigmented variant and other four showing acanthotic variant whereas Sonam SK et al (2011)[10] study observed no other variant of Seborrheic keratosis. On histopathologically tumour showed epidermis with hyperkeratotic, acanthotic with intraepidermal pseudohorn cyst filled with keratin and proliferation of basaloid cells mixed with squamoid cells

In the present study Basal Cell Carcinoma constitute 33.33% of all skin malignancies which is higher than Sonam SK et al (2011)[10]. Study where Basal Cell Carcinoma constitutes only 25.97% of all skin malignancy. The value was quite higher in Alakloby OM et al (1983)[13] study where basal cell carcinoma was 62% of all skin malignancy. We reported seven cases of Basal Cell Carcinoma, out of which one is pigmented variant and other was basosquamous variant of BCC. On histopathologically, we found island of hyperchromatic nuclei and scant cytoplasm with peripheral palisading arrangement, a retraction artifact separate the basaloid cells from the surrounding mucinous stroma.

Table-5: Comparison of Incidence of Adnexal Tumours.

Studied Observations	Benign		Malignant		Total no of Cases
	No	%	No	%	
Radhika K et al (2013)[14]	27	77.14	8	22.85	35
Sonam SK et al (2011)[10]	25	80.6	6	19.4	31
Ankit Sharma et al (2014)[15]	45	80.36	11	19.64	56
Rajalakshmi T et al (2013)[5]	53	77.94	15	22.05	68
Kaur A et al (2018)[16]	91	82.73	19	17.27	110
Paudyal P et al (2016)[17]	68	97.1	2	2.9	70
Deka M et al(2016)[18]	17	73.92	6	26.08	23
Present study	8	80	2	20	10

In the present study Benign Adnexal Tumours constitutes the majority (80%) which is similar to other India studies [5,10, 14-18].

Original Research Article

In the present study the benign sweat gland tumours constitute the most common (87.5%) among all benign skin appendageal tumours which is similar to other studies done by Ankit Sharma et al (42.86%) and Radhika K et al (48.15%) respectively [14,15].

In contrast with Sonam SK et al (2011) [10] study were Hair Follicle Tumour was found to be the commonest (52%) of all benign skin Appendageal skin tumours and Sanjay N Parate et al found Basal Cell Epithelioma as most common (55%) among all Benign Skin Appendageal tumours [8].

Proliferating Tricholemmal tumours was an extremely rare malignant tumour of follicular differentiation. Two cases of this tumour were reported in this study. In the study conducted by Paudyal P et al (2016) [17], showed 43 cases of Hair follicle tumours were benign. On histopathology tumour showed peripheral palisading of basaloid cells and large keratinocytes with eosinophilic cytoplasm and copious keratinization.

Intradermal nevus was the most common Benign Melanocytic Tumour in this study and similar observation was seen in Sonam SK et al (2011) [10] study.

The limitation of the study was for Special stain and immunohistochemistry can be utilized in situation where the diagnosis cannot be confirmed on Hematoxylin and eosin, such as typing of different adnexal tumours and melanoma. As molecular studies are not available in our set up, it was not possible to correlate histo- morphological findings with underlying genetic mutations leading to skin cancer.

Conclusion

Incidence of skin tumours constituted 4.14% of all tumours during five years period. It will highlight the rarity of this tumours. Most of the skin tumours are malignant with low incidence of benign tumour. It is always challenging to diagnose this tumours clinically. Histopathology is the gold standard to identify the architectural pattern of tumour and growth of infiltration to distinguish the malignant tumour. It is important to diagnose the malignant skin tumours due to its therapeutics and prognostic implications. The goal of improving diagnostic specificity will be achieved by detail histopathological finding; gross anatomical, molecular finding and long term follow up

Conflict of interest: Nil, **Source of Funding:** Nil, **Ethical Clearance:** Study was conducted after getting ethical clearance from Institutional Human Ethics Committee (IHEC) of Mahatma Gandhi Medical College and Research Institute, Pondicherry.

	Contributor 1	Contributor 2	Contributor 3	Contributor 4	Contributor 5
Concepts	√	√	-	-	-
Design	√	√	√	√	-
Definition of intellectual content	√	-	-	-	√
Literature search	√	-	-	√	√
Clinical studies	-	-	-	-	-
Experimental studies	-	-	-	-	-
Data acquisition	√	√	√	-	-
Data analysis	√	√		√	√
Statistical analysis	√	√	√	-	-
Manuscript preparation	√	√	-	-	-
Manuscript editing	√	√	√	-	√
Manuscript review	√	√	√	√	√
Guarantor	√	-	-	-	-

Funding: Nil, **Conflict of interest:** None initiated

Permission from IRB: Yes

References

1. Kumar V, Abbas KA, Fausto N, Aster JC. Robbins and Pathologic basis Cotran of disease. 4th ed. Philadelphia Elsevier, 2010.
2. Gundalli S, Kolekar R, Pai K, Kolekar A. Histopathological Study of Skin Tumours. International Journal of HealthcareSciences.2015March;2(2):155-163
3. Weinstock MA. Death from skin cancer among the elderly: epidemiological patterns. Arch Dermatol. 1997. 133 (10): 1207-1209.
4. McCourt C, Dolan O, Gormley G. Malignant melanoma: a pictorialreview. Ulster Med J.2014 May; 83 (2):103-10.
5. Tirumalae R, Roopa MO. Benignvs Malignant skin adnexal Neoplasms: How useful are silhouettes? Indian Journal of Dermatology. 2013Jan; 58(1):30-33.doi: 10. 4103/ 0019-5154.105282.
6. Kempf W, Hantschke M, Kutzner H, Burgdorf W. Dermatopathology. adnexal tumour Germany Springer 2008.
7. Roncalli De oliveria W, Neto CF, Rady PL, Tying SK. Seborrheic keratosis – like lesions in patients with epidermodysplasia verruciformis. J Dermatol. 2003 Jan; 30 (1): 48-53.
8. Sanjay N Parate, Rishi B Chahande, Suprita P Nayak and Sudhakar K Bobhate. Adnexal tumours of skin. Ind J Dermat.1998June ;43(2):58-60.
9. Le Boit PE, Burg G, Weedon D, Sarasin A. World Health Organization Classification of Tumours Pathology and Genetics of Skin Tumours. 3rd Edition. France: IARC Press, International Agency for Research on Cancer, 150 cours Albert Thomas, F-69008 Lyon, France; 2006.
10. Shaikh SS. Histopathological study of skin tumours (M.D thesis). Hubli Karnataka :2011.
11. Baruah B, Sengupta, Kesari SP, Ilapakurty B. Pattern on Non-Melanoma skin Cancer in Sikkim, India: 13-years clinicopathological review. Indian J Otolaryngol Head Neck Surg.2013July; 65 (suppl1): 160-162.
12. Deo SV, Sidhartha H, Shukla N K, Kumar S, Kar M, Samaiya A. Surgical management of skin cancers: Experience from a regional cancer centre in north India. Indian journal of cancer .2005 September;42(3):145-50.
13. Alakloby OM, Bukhari I A, Shawarby M.A. Histopathological pattern of Non–melanoma skin cancer at King Fahd Hospital of the university in the Eastern region of Saudi Arabia during the years 1983 to 2002. Cancer therapy.2008 May ;6(1) :303-306.
14. Radhika K, Phaneendra BV, Rukmangadha N, Reddy MK. A study of biopsy confirmed skin adnexal tumours:experience at a tertiary care teaching hospital. The Journal of Clinical and Scientific Research.2013 July; 2(3):132-8.
15. Sharma A, Paricharak DG, Nigam JS, Rewri S, Soni PB, Omhare A, Sekar P. Histopathological study of Skin Adnexal Tumours- Institutional Study in South India. Journal of Skin cancer.2014;1-4.
16. Kaur K, Gupta K, Hemrajani D, Yadav A, Mangal K. Histopathological analysis of skin adnexal tumors: A three year study of 110 cases at a tertiary care center. Indian J Dermatol. 2017Aug;62(4):400-6
17. Paudyal P, Agarwal M, Pradhan A, Sinha AK, Agrawal S.A clinico-histopathological study on skin appendageal tumors. Journal of Pathology of Nepal 2016; 6(11) : 885-91.
18. Deka M, Bhattacharjee S. Histopathology of Skin Adnexal Tumors- A Two Year Retrospective Study at a Tertiary Care Hospital. Int J Sci Stud .2016 Dec;4 (9): 61-65.

How to cite this article?

Samanta M, Mangal N, Bhavani K, Koteeswaran G, Parmar P.C. Histopathological study of skin tumours. Trop J Path Micro 2018;4(2):195-200. doi: 10.17511/jopm.2018.i2.14