

Case Report**Primary actinomycosis of the right upper extremity - an unusual presentation****Pratibha. S¹, Arundhathi. S², Lakshmi. K. S³, Praveen Kumar R⁴**

¹Dr. Pratibha. S., Assistant Professor of Microbiology, ²Dr. Arundhathi. S., Assistant Professor of Pathology, ³Dr. Lakshmi. K. S, Associate Professor of Pathology, ⁴Praveen Kumar R., Research Assistant, all authors are affiliated with Department of Microbiology, Sanjay Gandhi Institute of Trauma and Orthopedics, Bengaluru, Karnataka, India.

Corresponding Author: Dr. Arundhathi. S, Assistant Professor of Pathology, Sanjay Gandhi Institute of Trauma and Orthopaedics, Byrasandra, Jayanagar East, Bengaluru. Email id: arundhathi19@yahoo.co.in

.....

Abstract

Actinomycosis is a chronic disease characterized by multiple abscesses, granulomas, tissue destruction, extensive fibrosis and formation of sinuses. We report a case of 45 year old female with primary cutaneous actinomycosis of right upper extremity, which is a very rare site of occurrence. The patient was treated successfully with extended period antimicrobial treatment with Doxycycline (spacing) and Cefixime.

Key words: Actinomycosis, Abscess, Discharging sinus, Extremity, Swelling

.....

Introduction

Actinomycosis is a chronic disease characterized by multiple abscesses, granulomas, tissue destruction, extensive fibrosis and formation of sinuses. Actinomycosis in human beings is an endogenous infection. The actinomycotic species are present in mouth, intestine and vagina as commensals. Trauma, foreign bodies or poor oral hygiene favour tissue invasion. Actinomycosis most commonly occurs in three regions- Cervicofacial (55%), Abdominopelvic (20%) and Thoracic (15%) [1]. Involvement of other parts of the body is uncommon, usually secondary to lesion in one or other above mentioned sites.

Primary actinomycosis of an extremity is very uncommon with less than 50 case reports in the literature[1].

It can occur by secondary involvement through direct extension or hematogenous spread. Hematogenous dissemination can occur from common primary sites and is reported to occur in 3% of cases[2]. A case of primary actinomycosis of the right upper extremity in a 45 year old female is presented in this case report because of its rarity.

Case History

A 45 year old female laborer presented to Department of Orthopaedics with multiple discharging sinuses since 9 years, which started in right forearm and slowly involved right arm. Patient gave history of fall and injury to right arm and shoulder followed by development of multiple small wounds with purulent foul smelling discharge on the medial aspect of right arm and forearm which healed gradually to form scars. There was no history of cough, fever, loss of weight and discharge of bone spicules from sinuses. The patient was treated with several oral and injectable antibiotics in past 9 years before presenting to us.

On examination, patient was afebrile and her systemic examination was within normal limits. Local examination revealed multiple discharging sinuses over right arm and forearm with a few puckered scars (fig 1a & 1b). There was deformity of right arm due to fracture of shaft of right humerus. The skin was indurated, hyper pigmented and with a few healed fistulous tracts. The left upper limb was normal. There was no palpable lymphadenopathy and distal neurovascular deficit.

Manuscript received: 4th January 2018
Reviewed: 14th January 2018
Author Corrected: 20th January 2018
Accepted for Publication: 25th January 2018

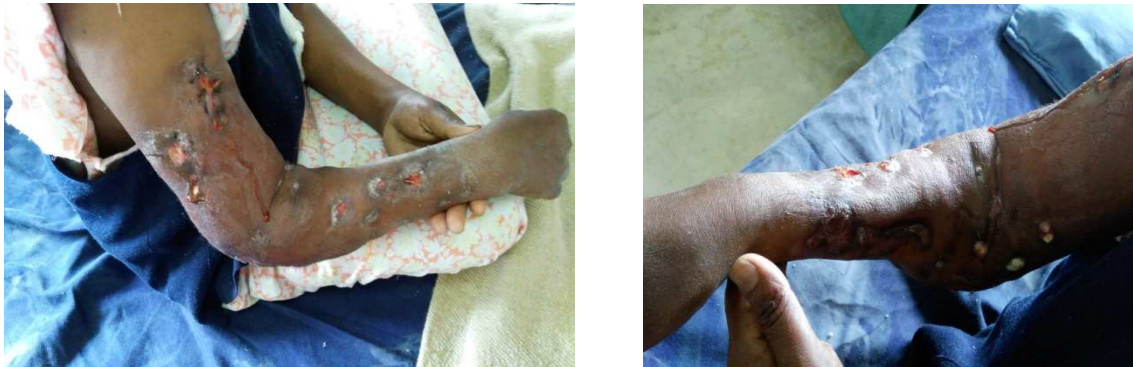Case Report

Fig 1a & 1b: Clinical picture showing multiple discharging sinuses involving right arm and forearm.

Laboratory findings revealed raised total leucocyte count of 15,600/cumm, with neutrophils 69%, lymphocytes 25%, eosinophils 3%, monocytes 3%. Hemoglobin was 10.0gms%, PCV 32%, ESR 40 mm/hr, random blood glucose 101mg/dl, blood urea nitrogen 20mg/dl, serum creatinine 1.1mg/dl, serum uric acid 7.7mg/dl. Serum electrolytes were within normal limits. SGOT 55U/L (5-35), SGPT 40U/L (5-35), Alkaline phosphatase 256 U/L (53-128), C - reactive protein 19.0mg/dl (0-0.6mg/dl) [1:2 dilution by turbidometry method].

Provisional diagnosis of osteomyelitis of right humerus with pathological fracture was made. Biopsy was performed under general anaesthesia and patient was treated with injectible cefaperzone+ sulbactam 1.5gm and Amikacin 500mg twice daily for 7days. She was advised non weight bearing until further orders, along with continuous physiotherapy. Tissue from sinus tract was sent for histopathology, Gram's stain and culture and sensitivity.

Biopsy from the discharging sinuses revealed bony trabaculae with mixed inflammatory infiltrate consisting of neutrophils, macrophages and lymphocytes. Actinomycotic colonies with Splendore-Hoeppli phenomenon were seen with suppurative granulomas composed of multinucleated giant cells, epithelioid cells, lymphocytes and neutrophils. Also seen were areas of necrosis which was suggestive of Actinomycotic osteomyelitis [fig 2].

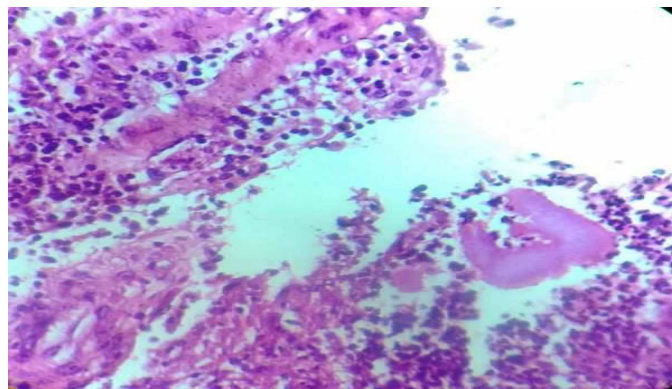


Fig-2.: Actinomycotic colonies with Splendore- Hoeppli phenomenon (H &E, 40X)

Gram stain done on section from paraffin block revealed many pus cells with a few Gram positive filamentous bacilli with club shaped structures suggestive of Actinomycosis (Actinomycetoma of right hand)[fig 3].

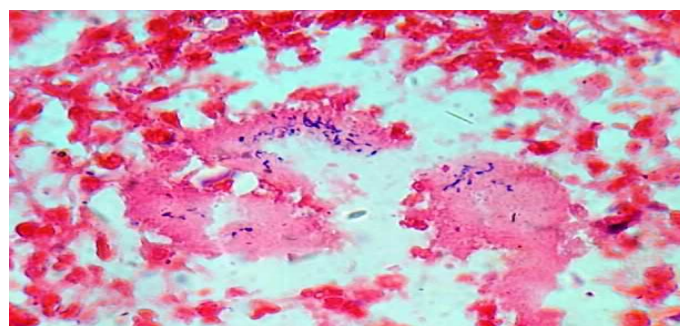


Fig-3.: Gram positive filamentous structures along with club shaped structures (Gram's stain, 100X)

Case Report

Modified ZN stain was negative (with 1% H₂SO₄). Culture of pus from discharging sinuses yielded scanty growth of spidery colonies after 72 hrs but colonies failed to survive on further incubation anaerobically. With this we confirmed it as primary actinomycosis of right upper extremity. Finally, patient was started on injectible Cef zone S 1.5gm and Amikacin 500mg twice daily for 7 days, later advised to take oral Doxycycline and Cefixime for 6 months. The patient responded well to treatment and the sinuses healed with scars [fig 4a & 4b].

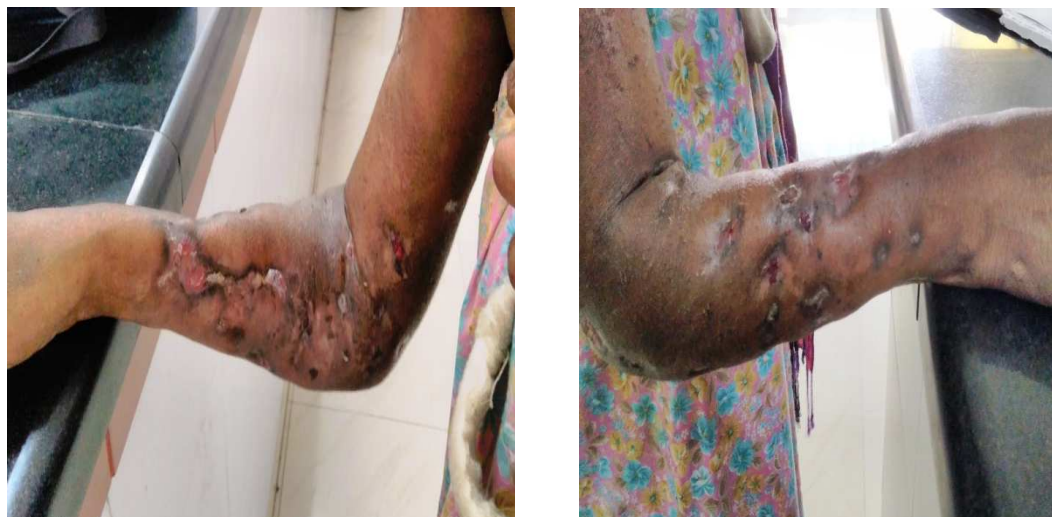

Fig-4a & 4b: Clinical picture showing healed sinuses with scars

Discussion

Actinomycosis is a rare infection primarily caused by Gram positive, non-spore forming, and anaerobic bacillus of *Actinomyces* species. It is primarily a commensal in oral cavities, including tonsillar crypts, dental plaques, caries teeth and female genital tract [1]. Infection occurs after trauma that creates an anaerobic condition predisposing to this microorganism and is commonly associated with other bacterial infections. It is characterized by chronic granulomatous suppurative microabscesses and draining sinuses. It easily spreads to adjacent structures and organs. Because of the exclusive endogenous habitat of the etiologic agent, head and neck, thorax and abdomen are the commonly involved sites [1]. Actinomycete is less virulent than other bacteria and requires a non-intact skin to invade and an anaerobic environment to cause illness. Sulfur granules (grains) containing filamentous or club shaped structures that are Gram positive but acid-fast negative are found in pus and tissue specimens [1].

Actinomycosis involving extremities is rare but has been reported in literature. Only few cases from an infection in the hand and wrist have been reported [3, 4].

Actinomycosis has been called the “most misdiagnosed disease” and has been a diagnostic challenge even to most experienced clinicians. Its chronic and indolent course resembles that of tuberculosis, fungal infection, malignancy and delays early diagnosis and treatment

[5]. This was the scenario in our case too where patient was misdiagnosed and was started on antitubercular drugs before histopathology, Gram’s stain smear, Zeihl Nielsen stain smear and Culture results were available.

An appropriate diagnosis of actinomycosis requires a combination of microbiological, pathological and molecular studies. The clinical diagnosis starts with obtaining a sample of suppurative exudate, tissue or sulphur granules. It is imperative that antibiotic therapy to be withheld until the sample/ specimen is obtained or else actinomyces may not be isolated. Diagnosis of Actinomycosis is considered when a direct Gram stain of the suppurative exudates or histologic section shows Gram positive, non – acid fast rods in diphtheroidal arrangements with or without branching [2].

Osteomyelitis due to *Actinomyces* has been reported infrequently in adults [6]. Bone involvement occurred in 1 - 15% of those series reviewed by Lewis and associates [7]. Hematogenous spread of actinomyces with extra osseous granuloma formation and minimal sub periosteal bone reaction has been reported by Gholamreza R et.al [8]. The diagnosis of actinomycotic osteomyelitis often is overlooked because of this entity’s ability to mimic other conditions.

Actinomyces species are susceptible to many antibiotics in vitro. Clinical experience supports Penicillin as the

Case Report

drug of choice, and in order to avoid relapse, prolonged treatment is advisable. Therapy should be individualized, but high doses (18-24 million units/day) of Penicillin over a long period of time (2-6 weeks) followed by oral therapy with Penicillin or Amoxicillin to complete 6 to 12 months seems reasonable. However there are some reports of successful short term treatment with B-Lactam antibiotics in special circumstances. In penicillin-allergic patients, Doxycycline, Minocycline, Tetracycline, Clindamycin, Erythromycin and Cephalosporins have been proven to be effective [9]. In our case the patient was successfully treated with long term Doxycycline and Cefixime. The prognosis is good if recognized and treated early as hematogenous dissemination is a frequent complication of actinomycosis.

Conclusion

In summary, this case report emphasizes the importance of early diagnosis with histopathology, Gram stain and culture. This case report also enlightens that delayed treatment can lead to increased morbidity and even mortality as actinomycosis mimics several other diseases and acts as “a great mimicker”. Involvement of upper extremity by actinomyces though rare is well documented and has to be ruled out.

Funding: Nil, **Conflict of interest:** None initiated,

Permission from IRB: Yes

References

1. Ching-Huei Yang. Primary Cutaneous Actinomycosis Of An Extremity: A Case Report J Intern Med Taiwan 2010;21:290-293.
2. Jacob Bettsworth, Kirandeep Gill, Jayesh. Primary Actionomycosis of the Foot: A Case Report and

Literature Review. Journal of the American College of Certified Wound Specialists 2009; 1:95-100.

3. Fayman M, Schein M, Braun S. A foreign body related actinomycosis of a finger. J Hand Surg Am. 1985 May;10(3):411-2.
4. Blinkhorn RJ Jr, Strimbu V, Effron D, Spagnuolo PJ. 'Punch' actinomycosis causing osteomyelitis of the hand. Arch Intern Med. 1988 Dec;148(12):2668-70.
5. Z Singh Kundu, R Singh, P Rana, R Bala, S Sangwan, P Walecha. Actinomycosis of Hand and Wrist: A Case Report. The Internet Journal of Orthopedic Surgery.2006;5(1).
6. Ashok R Nayak, ShreepadKulkarnil, Gireesh P Khodnapurand Vinayak Santosh. Actinomycotic Fungal Infection of Foot – A Case Report. IJBAR 2013; 04 (12): 946-949.
7. Lewis MAO, Macfarlane TW, McGowan DA. A microbiological and clinical review of the acute dentoalveolar abscess. British Journal of Oral and Maxillofacial Surgery 1990; 28 (6): 359-366.
8. Gholamreza R, et al. Actinomycosis may be presented in unusual organs – report of two cases. Journal of clinical and Diagnostic Research 2009; 3(6): 1938-1941.
9. Francisco Acevedo, Rene Baudrand, Luz M. Letelier, Pablo Gaete. Actinomycosis: a great pretender. Case reports of unusual presentations and a review of the literature. International Journal of Infectious Diseases; 2008; 12: 358 – 362.

How to cite this article?

Pratibha. S, Arundhathi. S, Lakshmi. K. S, Praveen Kumar R. Primary actinomycosis of the right upper extremity - an unusual presentation. Trop J Path Micro 2018;4(1):59-62.doi: 10.17511/jopm.2018.i1.10.